

Easy Method of Ryles Tube Insertion in Laparoscopic Surgeries under General Anesthesia: A Simple, Non fussy and Practical Approach

Ramsali Manjula V¹, Vanagondi Sivakumar², CG Raghuram³, Kulkarni Dilip Kumar⁴, Vankaylapatti Sarada Devi⁵, Pasupuleti Surender⁶

^{1,5}Associate Professor, ⁴Professor, ⁶Professor and HOD, Department of Anaesthesia, Malla Reddy Medical College for Women and Malla Reddy Narayana Multi Speciality Hospital, Suraram, Jeedimetla, Hyderabad, Telangana 500055, India. ³Professor, Department of Anaesthesia, Kurnool Medical College, Kurnool, Andhra Pradesh 518002, India. ²Assistant Professor, Department of Anaesthesia, Mallareddy Institute of Medical Sciences, Hyderabad, Telangana 500055, India

Abstract

Background: Insertion of Ryles Tube (RT) or orogastric tube and deflating the gastric contents is often required in patients of laparoscopic surgeries. Passing the RT into the stomach is always difficult in an anesthetized and intubated patients as they cannot follow the commands. Various techniques have been tried with variable success. **Aim:** We describe here a simple and easy technique of RT or orogastric tube insertion in paralyzed and intubated patients and compared with the conventional method in terms of success rate, attempts, time taken for insertion and adverse effects. Patients in our study included were those coming for laparoscopic surgeries under general anesthesia. **Methods:** A total of 60 patients undergoing laparoscopic surgeries, requiring RT placement of either sex, between the age group 25 and 55 yrs. were enrolled for our study. Patients were allotted into Two Groups. Group C (control) the RT was passed through the mouth, and in Group ET (study) RT was passed through the red rubber endotracheal tube. Demographic parameters, required number of attempts, placement time and adverse events were noted. **Results and Conclusions:** Our method of passing RT into the stomach in anesthetized and paralyzed patients- through the endotracheal tube is very simple and easy. The attempts and the time taken for insertion of the RT was much less in our method. The adverse effects were negligible with this method as compared to the conventional method.

Keywords: Ryles Tube (RT); Insertion; Endotracheal tube; Gastric contents; and Laparoscopy.

How to cite this article:

Ramsali Manjula V, Vanagondi Sivakumar, CG Raghuram, et al. Easy Method of Ryles Tube Insertion in Laparoscopic Surgeries under General Anesthesia: A Simple, Non fussy and Practical Approach. Indian J Anesth Analg. 2020;7(1 Part -I):64-69.

Introduction

Decompression of the stomach and GIT is requested quite often by the laparoscopic surgeon to facilitate a better laparoscopic view of the abdominal contents. A request is often made to the

Anesthesiologist at the head end to pass a RT in the anesthetized, intubated patients. RT insertion is difficult with first attempt of failure rates of nearly 50-60%^{1,2} by conventional method with the head in an intubating position. Anesthetized intubated patients cannot follow the instructions

Corresponding Author: Vanagondi Sivakumar, Assistant Professor, Department of Anaesthesia, Mallareddy Institute of Medical Sciences, Hyderabad, Telangana 500055, India.

E-mail: vskanaesth@yahoo.com

Received on 03.09.2019, **Accepted on** 02.11.2019

to swallow like awake patients so may not help in the easy insertion of the RT. This procedure is very challenging in anesthetized patients. The RT passed through nasal or oral route in anesthetized and paralyzed patients coils at piriform sinuses and the arytenoids cartilages.³

The distal part of the RT with multiple apertures becomes the weakest part of the tube and thus susceptible to kink, coil, knot or false passage.^{4,5} Several modifications have been tried for insertion of the RT but with less success at the cost of complication such as mucosal bleeding, sympathetic stimulation with rise in heart rate and blood pressure. These adverse effects may be not acceptable in high-risk patients.

Many a times attempts to pass the Ryles tube through the nose ends in a fiasco as the Ryles tube either refuses to go down the oesophagus or curls out of the oral cavity or coils into knots in the oral cavity. Repeated attempts through both the nostrils ultimately can lead to a messy situation in the oral cavity with epistaxis and bruising of nasal and oral pathways. A simple and easy technique is described here to ensure a successful RT passage into the stomach in laparoscopic surgeries in anesthetized patients.

Materials and Methods

The present study was conducted in our institute after receiving the permission from ethics committee. Sixty patients posted for laparoscopic surgeries under general anesthesia, aged between 18 and 55 yrs with ASA Grade I/II and MP Grade ½ were included in our study. Airway abnormality, upper airway lesions, skull base lesions, bleeding and clotting disorders, platelet disorders, oesophageal varices or stenosis or history of radiotherapy of head and neck region were excluded from the

study. All the patients were examined one day before surgery. The study procedure and the expected complications were discussed with the patients and informed consent was taken. On the day of the surgery in the operation theatre after all the monitors are connected, premedication was done with glycopyrrolate (0.01 mg/kg), midazolam (0.03 mg/kg) and ondansetron 4 mg intravenously. Fentanyl (2µ/kg) was given and then induced with propofol (2 mg/kg) after which muscle relaxant vecuronium (0.1 mg/kg) was injected once we could ventilate the patient. After adequate muscle relaxation, intubation was done with appropriate sized endotracheal tube and then connected to the ventilator after confirming the tube position. Anesthesia was maintained on intermittent positive pressure ventilation with N₂O and O₂, isoflurane and intermittent vecuronium.

Patients were randomly allocated to two groups: Group C (control) and Group ET (study). In control group the RT was passed through the mouth along the side of intubated endotracheal tube, and in study group-first the plain red rubber endotracheal tube of (size 7) was passed then RT was introduced through that (Fig. 1). In both the groups the RT used was made stiff by keeping in the freezer compartment of refrigerator for minimum 3-4 hrs.

The time taken for insertion was noted in seconds from the insertion of RT or endotracheal tube at the angle of the mouth to successful placement and verified by epigastric auscultation or aspiration of gastric contents.

The following data were recorded and calculated:

1. Success rates of the selected technique for the first attempt, second attempt, and overall;
2. Time required for the successful first attempt;
3. Adverse events during the procedure - coiling, kinking and bleeding.

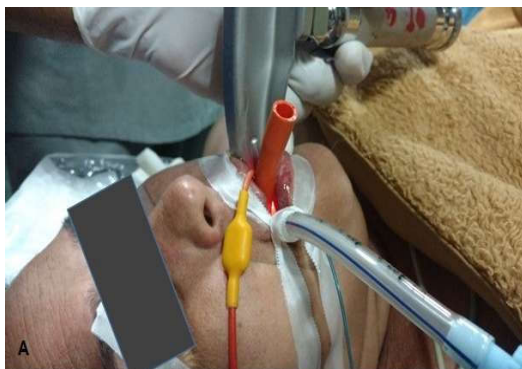

Fig. 1a: Passing of endotracheal tube into the oesophagus.

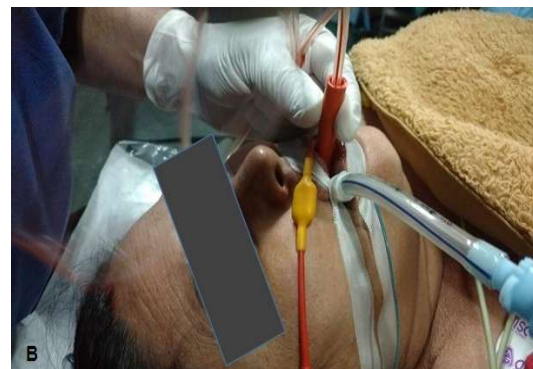


Fig. 1b: Passing of Ryles Tube through the endotracheal tube into the stomach.

Statistical analysis

The sample size was calculated by using effect size of 0.99, $\alpha = 0.05$, $1-\beta = 0.90$. The total sample size was 46 that is 23 in each group for using 't' test for two independent groups. However, because of possibility of dropout cases, we have taken total of 60 cases 30 in each W groups.

Observed data were entered in the Microsoft excel sheet. Demographic data (age, height, weight) were presented in mean and standard deviation and analyzed with unpaired *t*-test. ASA physical status, MP Grades, gender distribution, insertion attempts and adverse events were presented as frequency and analyzed by Chi-square test. Time required for insertion was analyzed again by unpaired *t*-test. Results with *p*-value < 0.05 were considered statistically significant.

Results

The study was conducted in total of 60 patients. The demographic parameters like age, sex, height, weight, ASA and MP Grade were comparable in both the Groups.

As shown in Table 2 the RT insertion in the first attempt was 26 (86.7%) in the study group. Second and third attempt requirement was more with the conventional method which is statistically significant. The procedure time for RT placement was least (Fig. 2) in the study (ET) Group (31.68 ± 14.96 seconds) in comparison to the control group (44.63 ± 23.80 seconds) and is significant.

Adverse effects like coiling, kinking and bleeding were negligible in our method as in Table 3. Coiling and Kinking was significantly higher in control group and compared to the study group ($p = 0.015$ and 0.030).

Coiling of the RT was observed in 6 (20%) patients only in the conventional technique and did not occur in the study group. Kinking occurred in 7 (23.33%) and 1 (3.33%) patients in control and ET assisted group respectively resulting in statistically significant difference. Four patients in control group and 2 in study group were observed to have mucosal bleeding.

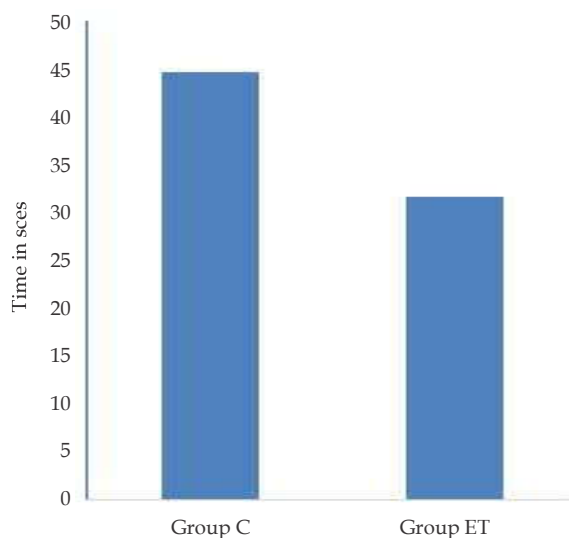


Fig. 1: RT Insertion Time

Table 1: Demographic Parameters

Parameters	Group C (Mean \pm SD)	Group ET (Mean \pm SD)	<i>p</i> - value
Age	34.8 \pm 10.61	40.67 \pm 15.55	0.093
Height	155.53 \pm 9.11	156.73 \pm 8.46	0.599
Weight	58.40 \pm 10.28	56.33 \pm 8.01	0.388
ASA Grade I/II	13/17	16/14	0.067
MP Grade I/II	18/12	21/09	0.293
Sex Ratio M/F	19/11	20/10	0.787

p - value < 0.05 is statistically significant

Table 2: Procedure Variables

Insertion Parameters		Group C	Group ET	<i>p</i> - value
Attempts	First	17 (56.7%)	26 (86.7%)	0.001*
	Second	10 (33.3%)	3 (10%)	
	Third	3 (10%)	1 (33.33%)	
Time (Mean \pm SD)		44.63 \pm 23.80	31.68 \pm 14.96	0.014*

**p* - value < 0.05 is statistically significant

Table 3: Adverse events of Ryles Tube insertion

Adverse Events	Group C	Group ET	<i>p</i> - value
Coiling	7 (23.33%)	0 (0)	0.015*
Kinking	8 (26.67%)	1 (3.33%)	0.030*
Bleeding	4 (13.33%)	2 (6.67%)	0.667

**p* - value < 0.05 is statistically significant

Discussion

The number of laparoscopic procedures are increased with the improvement in the laparoscopic skills and the facilities available. Anesthetists are required to pass the RT to decompress gastric contents, which obscures the view of camera and during laparoscopic surgery and chances of gastric perforation. The RT passed through nasal or oral route in anesthetized and paralyzed patients coils at piriform sinuses and the arytenoids cartilages.³ The weak part of the tube due to multiple apertures makes it susceptible to kink, coil and knot.

The whole concept is simple and straight forward. An appropriate sized endotracheal tube is passed through oral cavity either with the aid of a laryngoscope or blindly (after sufficiently lubricating ET tube) into the oesophagus. RT is then guided through the ET. This technique is almost always easy as already an endotracheal tube is in the trachea and the second ET can only be guided like an endoscope into oesophagus.

The oral, proximal end of the tube's lumen is filled with a small amount of jelly lubricant and through this, a RT is guided down the endotracheal tube to emerge out of the bevel and then into the stomach. Later, the endotracheal tube is pulled out over the RT till it comes out of the oral cavity. The RT is anchored just like an endotracheal tube till the end of the surgery.

Tail piece

In most of the laparoscopic surgeries, at the end of the surgery, the Ryle's tube is almost always removed either before or after extubation. Hence, there is no need to resort to a nasal route for passing

a Ryle's tube and also persist with that, when it has turned out to be messy. What all is needed is only decompression of GIT and that can be precisely and easily achieved by passing a Ryle's tube through an oral endotracheal tube stationed in the oesophagus. This Ryle's tube can obviously go only into the stomach and not elsewhere, as already an endotracheal tube is *in situ* in the trachea.

Insertion of the RT by conventional method in paralyzed, anesthetized and intubated patients usually a difficult task requiring repeat attempts leading to frustration and agony. The tube may get impacted into the pyriform sinus, arytenoids cartilage or trachea. The impaction of kinking, coiling and entanglement sometimes complicates the situation.⁶⁻⁸ Even in unintubated patients, the tube may coil around the epiglottis and lead to choking, respiratory distress, tachypnoea and cyanosis leading to morbidity.⁹

Several methods have been described for RT insertion with varying degree of success. The most common technique practiced in day to day practice is blind nasal insertion while maintaining external laryngeal manipulation or under direct vision using a laryngoscope followed by instrumentation with Magill's forceps. The nasogastric tube has been inserted with reliable and success rate (94% and 98% in first and second attempts respectively) with the help of stylet tied together at the tips by the slipknot.² in the literature different methods and their combinations have been reported. The method of rightward pull of the cricoid cartilage while maintaining mild flexion of the patients neck has found helpful for unconscious intubated patients.¹⁰ Oesophageal guidewire-assisted nasogastric tube insertion was done in anesthetized and intubated patients with manual displacement of larynx

(reverse sellick's) and found to have highest success rate of 99.2% in comparison to the technique of head flexion and lateral neck pressure.¹¹ In conscious and cooperative patients RT insertion either oral or nasal route is usually performed with 'push and swallow' technique.¹²

Our technique of RT insertion through ET showed to have more success rate on a first attempt insertion as compared to conventional method. Similar results were observed with Kwon et al.¹³ who studied insertion of orogastric tube through ET assistance. They studied to have favourable outcome with ET assisted orogastric tube placement as compared to conventional method of nasogastric tube insertion. Orogastric tube insertion using the new gastric tube guide study was done in manikin by Alflen et al.¹⁴ They concluded that, use of gastric tube guide to place orogastric tube in a simulation manikin had a higher success rate.

Total time of successful placement was much less in our study (ET) group than the control group (Fig. 2). Significantly shorter time was required for orogastric tube placement time in manikins in another study.¹⁴ The results coincides with our study results. Kwon et al.¹³ found to save more time in orogastric tube placement with ET assisted technique. This was the study done in emergency department where the patient required placement of orogastric tube for getting access to the stomach for diagnostic and therapeutic purposes, medication administration, GI feeding, gastric lavage after poisoning or overdose, gastrointestinal decompression for small bowel obstruction and also for evaluating GI bleeds. Gastric tube placement in unconscious and anesthetized patients was difficult and traumatic and so several modified technique were tried with neck flexion along with application of lateral pressure, a tied intubation stylet to an nasogastric tube or inserting a urethral guidewire or angiography catheter into the nasogastric tube.^{4,7,15} Some authors also suggested stiffening the RT by keeping in the refrigerator.¹⁶⁻¹⁸

The chances of adverse events like coiling and kinking were much less in Group ET than in the Group C. This was mainly because the longer length of the ET tube, the passage of RT was easy probably avoiding coiling and kinking. Various other studies have observed that complications like coiling and kinking were common with nasogastric tube insertion without instrumentation.⁴⁻⁶ Repeated attempts have been reported to increase with incidences of bleeding. The same was observed in our study with less incidences of multiple attempts and bleeding. Kwon et al.¹³ concluded in their study

to have to have mucosal bleeding with ET assisted placement of the orogastric tube than the control method. These results were in contrary to our study results. In guidewire assisted technique, there are less chances of coiling and no kinking according to Mohan Chandra Mandal et al.¹⁵ but more chances of bleeding. With flexion of neck and reverse Sellick's approach, there were very less chances of kinking and bleeding with shorter time for insertion.

Conclusion

Our technique of RT insertion showed higher success rate and less time of placement. Even the adverse events were much less compared to the conventional method. So, we conclude that our method of RT insertion into the stomach in anesthetized and paralyzed patients through assisted endotracheal tube is simple, non-fussy and faster with lesser adverse events.

References

1. Bong CL, Macachor JD, Hwang NC. Insertion of the nasogastric tube made easy. *Anesthesiology* 2004 Jul;101(1):266.
2. Tsai YF, Luo CF, Illias A, Lin CC, Yu HP. Nasogastric tube insertion in anesthetized and intubated patients: a new and reliable method. *BMC Gastroenterol.* 2012;12:99.
3. Ozer S, Benumof JL. Oro- and nasogastric tube passage in intubated patients: fiberoptic description of where they go at the laryngeal level and how to make them enter the esophagus. *Anesthesiology.* 1999;91(1):137-143.
4. Appukutty J, Shroff PP. Nasogastric tube insertion using different techniques in anesthetized patients: A prospective, randomized study. *Anesth Analg* 2009 Sep;109(3):832-35.
5. McConnell EA. Inserting a nasogastric tube. *Nursing* 1997 Jan;27(1):72.
6. Illias AM, Hui YL, Lin CC, et al. A comparison of nasogastric tube insertion techniques without using other instruments in anesthetized and intubated patients. 2013 Sep-Oct;33(5):476-81.
7. Hung CW, Lee WH. A novel method to assist nasogastric tube insertion. *Emerg Med J* 2008 Jan;25(1):23-25.
8. Tai CM, Wang HP, Lee CT, et al. Esophageal obstruction by a tangled nasogastric tube. *Gastrointest Endosc* 2010 Nov;72(5):1057-1058.
9. Agarwal A, Gaur A, Sahu D, Singh PK,

- Pandey CK. Nasogastric tube knotting over the epiglottis: a cause of respiratory distress. *Anesth Analg*. 2002;94(6):1659-660.
10. Ghatak T, Samanta S, Baronia AK. A new technique to insert nasogastric tube in an unconscious intubated patient. *N Am J Med Sci* 2013 Jan;5(1):68-70.
 11. Kirtania J, Ghose T, Garai D, et al. Esophageal guidewire-assisted nasogastric tube insertion in anesthetized and intubated patients: A prospective randomized controlled study. *Anesth Analg* 2012 Feb;114(2):343-48.
 12. Fakhari S, Bilehjani E, Negargar S, et al. Split endotracheal tube as a guide tube for gastric tube insertion in anesthetized patients: A randomized clinical trial. *J Cardiovasc Thorac Res* 2009;1:17-22.
 13. Kwon OS, Cho GC, Jo CH, et al. Endotracheal tube - assisted orogastric tube insertion in intubated patients in an ED. *Am J Emerg Med* 2015 Feb;33(2):177-80.
 14. Christian Alflen, Marc Kriege, Irene Schmidtman, et al. Orogastric tube insertion using the new gastric tube guide: First experiences from a manikin study. *BMC Anesthesiology* 2017 Apr 4;17(1):54.
 15. Mandal MC, Dolai S, Ghosh S. Comparison of four techniques of nasogastric tube insertion in anesthetized, intubated patients: A randomized controlled trial. *Indian J Anesth* 2014;58:714-18.
 16. Ratzlaff HC, Heaslip JE, Rothwell ES. Factors affecting nasogastric tube insertion. *Crit Care Med*. 1984;12(1):52-53.
 17. Flegar M, Ball A. Easier nasogastric tube insertion. *Anesthesia* 2004 Feb;59(2):197.
 18. Gombar S, Khanna AK, Gombar KK. Insertion of a nasogastric tube under direct vision: Another atraumatic approach to an age-old issue. *Acta Anesthesiol Scand* 2007 Aug;51(7): 962-96.
-
-